

# A prospective clinical evaluation of mandibular lingual retainer survival

Tülin Taner and Muge Aksu

Department of Orthodontics, Faculty of Dentistry, University of Hacettepe, Ankara, Turkey

Correspondence to: Muge Aksu, Department of Orthodontics, Faculty of Dentistry, University of Hacettepe, Sıhhiye, Ankara 06100, Turkey. E-mail: muge.aksu@hacettepe.edu.tr

**SUMMARY** Bonded retainers are considered reliable, independent of patient co-operation, and highly efficient. However, most studies regarding the survival of retainers are retrospective. The aims of this investigation were to prospectively evaluate the failure rate of bonded lingual retainers, the influence of direct or indirect bonding procedures on survival, and to determine the distribution of failures over a 6 month period. Mandibular lingual retainers were bonded in 66 patients. Thirty-two retainers were bonded using a direct method and 34 by an indirect method. There were 23 females and 9 males (mean age  $15.96 \pm 3.21$  years) in the direct group and 29 females and 5 males (mean age  $19.44 \pm 6.79$  years) in the indirect group. A  $0.016 \times 0.022$  inch Bond-a-Braid retainer wire (eight-braided, flattened, stainless steel dead soft wire) was used with Transbond LR. Following bonding, the patients were observed monthly. A chi-square test was used to analyse the influence of the direct and indirect procedures on survival rate.

Twenty-five retainers failed. The failure rate was 46.9 per cent with the direct method and 29.4 per cent with the indirect method. The difference between the methods was not statistically significant. The total failure rate was 37.9 per cent. The highest failure rate was seen in the first month. Seven patients had repeated failures. The failure rate was higher in the right quadrant. The total survival rate was 62.1 per cent.

## Introduction

The stability of the treatment result in the mandibular anterior region is important in orthodontics. To avoid relapse, various types of removable or fixed retainers are used for an extended period of time. The lower fixed retainer from canine to canine is one of the most commonly used methods of retention at the end of orthodontic treatment. Lingual wire soldered to canine bands for the fixed lower retainer has been used by orthodontists for many years. With the advent of new effective bonding materials, many orthodontists prefer to use canine-to-canine bonded retainers to obtain optimal retention of the lower anterior teeth both functionally and aesthetically. It has been thought that retainers bonded to six teeth are more efficient in preventing relapse. Labial movement of the anterior teeth occurs when the retainer is only bonded to canine teeth (Zachrisson, 1995; Störmann and Ehmer, 2002).

Bonding a segment of archwire to the lingual surfaces of the mandibular anterior teeth from canine to canine was originally proposed to improve the long-term stability of orthodontic treatment results. The major advantage of bonded canine-to-canine retainers is that they are compliance free. One major disadvantage is that the placement procedure is time consuming and technique sensitive (Zachrisson, 1977; Becker, 1987; Dahl and Zachrisson, 1991). Another technique-related problem is frequent bond failure, either at the wire/composite interface

if too little composite is added or at the adhesive/enamel interface in situations with moisture contamination or retainer movement during the bonding procedure (Zachrisson, 1977).

A number of studies have investigated the effects of retention variables on the survival of lingual retainers (Zachrisson, 1977; Årtun *et al.*, 1997; Lumsden *et al.*, 1999). The failure rates recorded in those investigations showed differences when various types of retainers or retainer wires were used (Zachrisson, 1977; Becker and Goultschin, 1984; Årtun *et al.*, 1997).

It has been reported that almost 50 per cent of breakages occur within the first year (Dahl and Zachrisson, 1991) and that the failure rate is highest within the first 6 months (Segner and Heinrici, 2000; Lie Sam Foek *et al.*, 2008). However, due to the nature of these retrospective studies, unknown or incomplete data may prevent detection of true fracture rates, and clinical information concerning application procedures is limited. Fixed lingual retainers are bonded using either the direct or the indirect method; however, no study has evaluated the bonding procedure as a cause of failure. Therefore, the objectives of this study were to evaluate the clinical survival rate of flexible, braided rectangular bonded lingual retainers during a 6 month follow-up period, to investigate the influence of direct or indirect bonding procedures on survival rate, and to determine the distribution of failures per month.

## Subjects and methods

This prospective study undertaken between 2004 and 2006 was based on assessment of 66 patients (52 females and 14 males) who required a fixed canine-to-canine retainer after undergoing fixed appliances orthodontic treatment. At the Department of Orthodontics, University of Hacettepe, fixed lingual retainers are routinely applied directly or indirectly after orthodontic treatment.

A standardized retention protocol was used for the subjects included in the study. All patients were informed about the retainer application procedures. To examine the influence of direct and indirect bonding procedures on bond failures, the patients were divided into two groups in the order of their debond time: the first patient was assigned to the direct and the next to the indirect group. There were 23 females and 9 males and 29 females and 5 males with mean ages of  $15.96 \pm 3.21$  and  $19.44 \pm 6.79$  years in the direct and indirect groups, respectively. In each group, an eight-braided, flattened, stainless steel dead soft wire (Bond-a-Braid,  $0.016 \times 0.022$  inch; Reliance Orthodontic Products, Itasca, Illinois, USA) was used as the retainer. All retainers were bonded using light cure adhesive (Transbond™ LR; 3M Unitek Orthodontic Products, Monrovia, California, USA) and a light-emitting diode (LED) curing unit (Elipar Free Light; 3M ESPE, St Paul, Minnesota, USA). The retainers were fabricated and placed according to a standardized protocol by senior and junior orthodontists.

Follow-up examinations were carried out monthly. The length of time the retainers remained in place without resin fracture or loosening from the teeth at one or more time points was evaluated. The study endpoint was 6 months after the retainer had been bonded.

### Application procedures

**Direct bonding group.** After debonding, a mandibular impression was taken. The retainer was initially prepared on plaster casts. The lingual surfaces of the teeth were pumiced, rinsed with water, and dried with compressed air. Two pieces of ligature wire were passed beneath the distal contact points of the lateral incisors and canines gingival to the archwire. This ligature wire passed over the archwire mesially and incisally following placement of the retainer on the lingual side of the teeth. The retainer wire was pushed into tight contact with the lingual surfaces of the anterior teeth and the ligature wires were twisted tightly in a clockwise direction (Zachrisson, 1995). The lingual surfaces of the anterior teeth were acid etched with 37 per cent phosphoric acid for 20 seconds per tooth, rinsed thoroughly, and then the bonding adhesive primer (Transbond™ XT) was applied. The retainer wire was bonded to the teeth using Transbond™ LR. The bonding procedure was carried out according to the manufacturer's instructions. On completion

of bonding, the ligature wires holding the retainer wire were cut and removed.

**Indirect bonding group.** The wire was bent as in the direct method. A high-quality separating medium was applied to the plaster cast model. The curved wire was waxed to the cast between the contact points of the canine and lateral incisor. Transbond™ LR was applied to the lingual surfaces of the incisors using the LED curing unit. Sufficient space was left for cleaning between the teeth. A mixture of light body silicone-based impression material was loaded onto the lingual surfaces of the incisors and around the retainer wire. After the impression material had set, a putty-body was applied over the light-body material that covered the incisal edges of the incisors. Following setting of the tray material, the tray was removed. Hot water was poured to remove the wax used to hold the retainer wire. The resin surfaces were sandblasted with  $90 \mu$  of aluminium oxide to remove the residual separating medium. The lingual surfaces of the anterior teeth were acid etched for 30 seconds per tooth and rinsed thoroughly as in the direct group. After drying, Maximum Cure A and B (Reliance Orthodontic Products) were applied to the etched surfaces of the teeth and sandblasted resin, respectively. The tray was placed in the mouth, pressing lightly against the teeth from the lingual. After 1 minute of setting time, the tray was removed (Haydar and Haydar, 2001).

### Follow-up

All patients were seen monthly. Failures of retainers as a result of debonding, fracture, debonding and fracture, or retainer loss were recorded. In all cases where debonding was recorded, rebonding was undertaken. When detachments occurred, the remnants of the adhesive were removed and the retainers were repaired at the chair-side.

### Statistical analysis

Statistical analysis was performed using the Statistical Package for Social Sciences (version 12.0; SPSS Inc., Chicago, Illinois, USA). Descriptive statistics were calculated.

A chi-square test was used to analyse the influence of the direct and indirect procedures on survival rate. *P* values less than 0.05 were considered to be statistically significant. The distribution of failure rates per month, the number of repeated bond failures, and the total distribution of failures in the right and left quadrants were calculated.

## Results

From the total of 66 patients, 25 (37.9 per cent) had failures at the end of 6 months. The failure rate was 46.9 per cent with the direct method and 29.4 per cent with the indirect method (15 patients from the direct and 10 patients from the

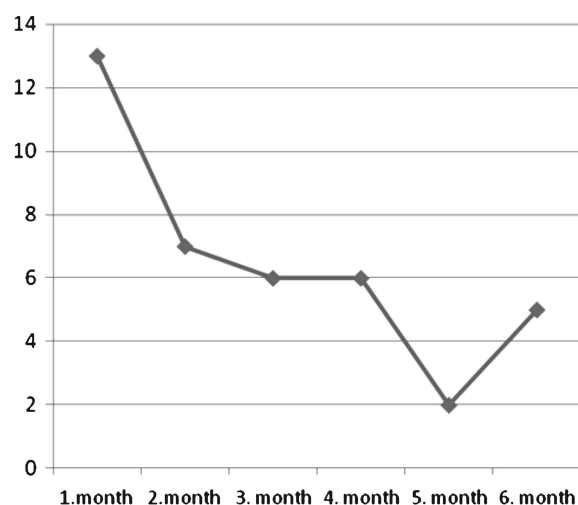
indirect bonding groups). The difference between the two procedures was not statistically significant ( $P > 0.05$ ; Table 1). The findings of the two groups were then combined and considered. The survival rate for the whole group was 62.1 per cent.

Figure 1 shows the failure rate of retainers in terms of subjects and Table 2 the distribution of failures on the lower

**Table 1** Comparison of survival of fixed retainers bonded directly or indirectly.

	Patients ( <i>n</i> )	Failure	%	Success	%	<i>P</i>
Direct	32	15	46.9	17	53.1	NS
Indirect	34	10	29.4	24	70.6	
Total	66	25	37.9	41	62.1	

NS, not significant.



**Figure 1** Distribution of bond failures per patient over time.

anterior teeth per month. The highest failure rate was seen in the first month, a total of 24 failures occurred in 13 patients. The highest rate was 33.3 per cent for the lower right central incisor. The lowest failure rate was observed in the fifth month, a total of three failures in two patients.

From the total of 25 patients who had failures, 7 (28 per cent) had repeated bond failures (Table 3). The failures were observed at different check-ups. Failures in the right quadrant were 56.6 per cent and in the left quadrant 43.4 per cent.

## Discussion

Fixed lingual retainers are widely used after orthodontic treatment in order to maintain the achieved result and prevent relapse. One of the drawbacks of these appliances is breakage or bond failure of the wire. In this prospective study, survival of fixed lingual retainers was investigated in terms of two different bonding procedures. The patients were observed carefully at monthly intervals. Thus, any loosening or detachment of the retainer was detected and recorded. Both retainer wire and the adhesive used in this study were identical in the direct and indirect bonding groups. The retainer wire was prepared on the dental casts before debonding and was bonded on each lower anterior tooth.

It has been reported that frequent bond failures occur within the first 6 or 12 months (Segner and Heinrici, 2000; Störmann and Ehmer, 2002). Therefore, it is important to be aware of changes that may occur during the early stages of retention since the mandibular incisors are most susceptible to relapse immediately after completion of orthodontic treatment (Reitan, 1969; Parker, 1972).

The total survival rate for lingual retainers was 62 per cent when a  $0.016 \times 0.022$  inch, eight-braided stainless steel wire was used in this prospective study. Lie Sam Foek *et al.*

**Table 2** The distribution of failures (per cent) occurring on the lower anterior teeth per month.

Lower anterior tooth failure (months)		Number of patients	Total failure	Right canine	Right lateral	Right central	Left central	Left lateral	Left canine
1	<i>n</i>	13	24	3	2	8	3	5	3
	%			12.5	8.3	33.3	12.5	20.8	12.5
2	<i>n</i>	7	18	1	5	5	3	3	1
	%			5.6	27.8	27.8	16.7	16.7	5.6
3	<i>n</i>	6	17	3	3	3	3	4	1
	%			17.6	17.6	17.6	17.6	23.5	5.9
4	<i>n</i>	6	7	0	2	2	2	1	0
	%			0.0	28.6	28.6	28.6	14.3	0.0
5	<i>n</i>	2	3	0	2	0	0	1	0
	%			0.0	66.6	0.0	0.0	33.3	0.0
6	<i>n</i>	5	7	0	2	2	2	0	1
	%			0.0	28.6	28.6	28.6	0.0	14.3

*n*, number of patients and teeth that had failure during the follow-up.

**Table 3** The distribution of repeated failures in seven patients.

Patient	Month 1	Month 2	Month 3	Month 4	Month 5	Month 6
B.S.	LR3, LR2, LR1	LR3, LR2	LR3, LR2, LR1, LL1, LL2, LL3			
G.U.	LR1, LL1	LR2, LR1, LL1, LL2				LR1, LL1
S.E.	LR1, LL2	LR1, LL2	LR1, LL2		LL1	LL3
A.T.		LR2, LR1, LL1, LL2			LR2, LL2	
N.T.	LR1		LR3, LR2, LR1, LL1, LL2			
O.B.	LR1			LR1		
E.E.E.	LL2, LL3	LR2, LL3				

LR3, lower right canine; LR2, lower right lateral; LR1, lower right central; LL1, lower left central; LL2, lower left lateral; LL3, lower left canine.

(2008) reported a higher survival rate at 6 months of 78 per cent with a three strand  $0.016 \times 0.022$  inch braided stainless steel wire, a less flexible wire when compared with the eight-braided wire used in this study.

The survival rate in this study was lower when compared with the results of long-term investigations. Although it is not possible to make direct comparisons, dimension and flexibility of the retainer wire may partly account for the differences. Dahl and Zachrisson (1991) reported a survival rate of 89.7 per cent for 0.0195 or 0.0215 inch three stranded and 94.1 per cent for 0.0215 inch five stranded wires after 6 and 3 years, respectively, and Årtun *et al.* (1997) a survival rate of 72.7 per cent with a 0.0205 inch wire after 3 years. Störmann and Ehmer (2002) found that the failure rate changed when different types of retainers were used. Their 2 year survival rates were 71 per cent with a 0.0195 inch wire and 47 per cent with a 0.0215 inch wire. Rose *et al.* (2002) reported a 90 per cent survival rate with a 0.0175 inch respond wire in their prospective study. Andrén *et al.* (1998) observed a higher survival rate with a 0.0195 inch wire than with a 0.015 inch retainer.

The type of composite and bonding agent are important factors on the failure rate of lingual retainers. In this study, the composite was Transbond LR and bonding agents were Transbond XT primer in the direct bonding group and Maximum Cure A and B in the indirect bonding group. As a variety of composite materials and bonding agents have been used when bonding fixed retainers, it is not possible to make comparisons (Dahl and Zachrisson, 1991; Segner and Heinrich, 2000; Rose *et al.*, 2002; Störmann and Ehmer, 2002; Lie Sam Foek *et al.*, 2008). However, in patients with higher survival rates (Dahl and Zachrisson, 1991; Årtun *et al.*, 1997; Störmann and Ehmer, 2002), a chemically cured adhesive (Concise) was used.

The effects of different bonding techniques have not been reported in the literature. This is the first study investigating whether different bonding techniques lead to different failure rates. The results show that the distribution of bond failure between the two types of bonding methods was not statistically significantly different. In the study of Karaman *et al.* (2003), the failure rate of retainers after indirect

bonding was reported to be 20 per cent. This lower bond failure rate might be due to the difference in bonding agent. Although there was no significant difference between the direct and indirect bonding procedure regarding failure rates, the indirect method has some clinical advantages such as reduced clinical time, more accurate placement of the retainer, patient comfort, and correct polymerization without moisture contamination.

Insufficient enamel–composite bond strength, such as moisture on the edges of the enamel or movement of the retainer wire during setting can be the cause of failure with direct bonding. In contrast, insufficient bond strength seen in the indirect procedure might be technique-related rather than a result of moisture control or movement of the wire. According to Årtun and Zachrisson (1982), possible reasons for failure include distortion of the wire during polymerization of the resin, too little adhesive, and direct trauma to the retainer.

The number and experience of the operators might be expected to influence the failure rates. Long-term failure rates have been reported to be infrequent when one or two-experienced orthodontist place the retainers (Dahl and Zachrisson, 1991; Årtun *et al.*, 1997; Rose *et al.*, 2002). Although a statistical comparison could not be performed, failure rates did not differ between different operators in this study. Similarly, Lie Sam Foek *et al.* (2008) reported that neither different operators nor experience played a significant role in failure.

The distribution of failures on the lower central and lateral incisors was more frequent than on the canines. The most likely explanation for the susceptibility of these teeth to failure might be the surface properties of the lingual sites since the concave form of the lingual surfaces might lead to insufficient wire–tooth contact.

Failure is more likely to occur at the adhesive–enamel interface. No breakage of the retainer wire was recorded during the observation period. This finding is similar to that of Lumsden *et al.* (1999).

Repeated failures are likely to occur on the same teeth even though they are rebonded. Insufficient patient care seems to be a possible reason for the repeated bonding since



in the present study, of the 25 patients with failure, 7 (28 per cent) had repeated bond failures. Rebonding might not provide sufficient bond strength due to the difficulties in removing the adhesive remnants under the wire.

Due to the relatively young age of the patients in this study, non-compliance might have a negative effect on bonding. Successful clinical outcomes were reported in an adult population who can be expected to comply with any instructions (Becker, 1987; Dahl and Zachrisson, 1991; Rose *et al.*, 2002). Detailed instructions on retainer use should be given to the patient during the initial phase of lingual retainer application.

The results of this prospective study confirm that regardless of the protocol used, failure of lingual retainers can occur even at the very early stages of retention. Thus, routine follow-ups after the end of orthodontic treatment are necessary. The use of different types of retainers and adhesive systems was not investigated in this study; however, these factors should also be taken into consideration.

When the groups were combined, it was found that breakage was slightly higher in the right than in the left quadrant. It must be taken into consideration that biting habits may affect the breakage.

Retainers bonded to six teeth have the inherent risk of bonding failure being unnoticed by the patient. During the early months, it is difficult to detect failure. Tooth mobility tests can be used to determine detachment of the retainer. As the duration between the time of failure and follow-up increases, the adhesive starts to change colour, becoming darker. A change in colour is another indication of bond failure.

Careful preparation and adaptation of the wire, along with strict moisture control and an adequate amount and distribution of adhesive, are all essential for bonded retainer success. Monthly follow-ups during the first 6 months are important to monitor any failure that might cause tooth movement. A further consideration may be to place the lower bonded retainer 1 month before the intended debond.

## Conclusions

1. Failures occurred in 37.9 per cent of patients during the 6 months observation follow-up.
2. There was no difference between the direct or indirect method regarding failure rate.
3. The highest bond failure was seen in the first month (33.3 per cent).
4. The lower incisors were more susceptible to breakage.
5. Twenty-eight per cent of the patients had repeated bond failures.
6. Failures in the right (56.6 per cent) were slightly higher than in the left (43.4 per cent) quadrant.

## Funding

Research Center Office of the Hacettepe University (03G020).

## References

- Andrén A, Asplund J, Azarmidokht E, Svensson R, Varde P, Mohlin B 1998 A clinical evaluation of long term retention with bonded retainers made from multi-strand wires. *Swedish Dental Journal* 22: 123–131
- Årtun J, Zachrisson B 1982 Improving the handling properties of a composite resin for direct bonding. *American Journal of Orthodontics* 81: 269–276
- Årtun J, Spadafora A T, Shapiro P A 1997 A 3-year follow-up study of various types of orthodontic canine-to-canine retainers. *European Journal of Orthodontics* 19: 501–509
- Becker A 1987 Periodontal splinting with multistrand wire following orthodontic realignment of migrated teeth: report of 38 cases. *International Journal of Adult Orthodontics and Orthognathic Surgery* 2: 99–109
- Becker A, Goultschin J 1984 The multistrand retainer and splint. *American Journal of Orthodontics* 85: 470–474
- Dahl E H, Zachrisson B U 1991 Long-term experience with direct-bonded lingual retainers. *Journal of Clinical Orthodontics* 25: 619–630
- Haydar B, Haydar S 2001 An indirect method for bonding lingual retainers. *Journal of Clinical Orthodontics* 35: 608–610
- Karaman A I, Polat O, Büyükyılmaz T 2003 A practical method of fabricating a lingual retainer. *American Journal of Orthodontics and Dentofacial Orthopedics* 124: 327–330
- Lie Sam Foek D J, Ozcan M, Verkerke G J, Sandham A, Dijkstra P U 2008 Survival of flexible, braided, bonded stainless steel lingual retainers: a historic cohort study. *European Journal of Orthodontics* 30: 199–204
- Lumsden K W, Saidler G, McColl J H 1999 Breakage incidence with direct-bonded lingual retainers. *British Journal of Orthodontics* 26: 191–194
- Parker G R 1972 Transseptal fibers and relapse following bodily retraction of teeth: a histologic study. *American Journal of Orthodontics* 61: 331–344
- Reitan K 1969 Principles of retention and avoidance of posttreatment relapse. *American Journal of Orthodontics* 55: 776–790
- Rose E, Frucht S, Jonas I E 2002 Clinical comparison of a multistranded wire and a direct bonded polyethylene ribbon-reinforced resin composite used for lingual retention. *Quintessence International* 33: 579–583
- Segner D, Heinrici B 2000 Bonded retainers—clinical reliability. *Journal of Orofacial Orthopedics* 61: 352–358
- Störmann I, Ehmer U 2002 A prospective randomized study of different retainer types. *Journal of Orofacial Orthopedics* 63: 42–50
- Zachrisson B U 1977 Clinical experience with direct-bonded orthodontic retainers. *American Journal of Orthodontics* 71: 440–448
- Zachrisson B J 1995 Third-generation mandibular bonded lingual 3-3 retainer. *Journal of Clinical Orthodontics* 29: 39–48